

Trepanation and artificial cranial deformations in ancient Armenia

Anahit Khudaverdyan

Institute of Archaeology and Ethnography, National Academy of Science, Republic of Armenia, Yerevan, 0025, Charents st. 15; E-mail: akhudaverdyan@mail.ru

ABSTRACT The purpose of the paper is to review surgical and ritual practices on people living on the Shirak Plateau (Armenia) during the Late Antiquity period (1st century BC – 3rd century AD) and is based on human remains uncovered at sites in Beniamin, Black Fortress I, Shirakavan, Karmrakar and Vardbakh. The basic demographic data for these cases, including the age and sex of the skeleton, the precise location of the trepanation, the form of the trepanation and instruments used, and the presence of any associated pathologies, injuries, diseases, or developmental deformities on the skeleton, are specified. The phenomenon of artificial skull and teeth modifications identified at ancient burials sites in Armenia clearly points to the emergence of social complexity and class differentiation, and hence the need for social distinction, which in this case was accomplished through the use of body markings. A compilation of case reports and information on trepanation and deformation is essential for a bioarcheological study of the procedure.

KEY WORDS: trephination, Shirak Plateau, modification of skulls, modification of teeth

Trepanation, is one of the most ancient medical “treatments” on living humans [Brothwell 1994]. It is known all over the world from prehistoric times, and is practiced even at the present time among some tribes especially in Africa, as reported, for example, by Lisowsky [1967] and Margetts [1967]. The reasons for trepanation in prehistoric to present times, among different peoples and cultures, are multiple. Hippocrates, as many other scholars after him, believed trepanation was done for the

relief of skull pressure on the brain, and was probably related to cranial trauma [Açikkol *et al.* 2009]. Broca [1876] suggested trepanation was often practised to cure mental disorders. Indeed, the aim of trepanation is still unknown; some of the discoveries, however, showed that it was used for healing purposes or symbolic ends [Erdal 2005]. Margetts [1967] found in Africa not only prophylactic trepanning but also a widespread use of cranial rondelles as amulets to protect against spirit

intrusion in the body. According to Ruffer [1918], cranial bone powder was thought by some “to possess curative properties”. *The Cambridge Encyclopedia of Human Paleopathology* [Aufderheide & Rodriguez-Martin 1998], cites four distinguishable methods of trepanation that include grooving, scraping, drilling, and cutting. The instruments and techniques used and the reasons for this practice have varied over time and location.

Deformation of the head in the living is a very old, if not the most ancient, cultural practice leading to changes in one’s natural morphology [Senyurek & Tunakan 1951, Ferembach 1970, Özbek 1974, Trinkaus 1983, Meiklejohn *et al.* 1992]. The deliberate insult on the cranial vault has been revealed by modification of the form of the head, which varies enormously in various ethnic groups depending on geographical and chronological factors. The time interval defining given findings corresponds to the 9th millennium BC – 3rd century AD [Khudaverdyan 2005; Lorentz 2010]. It was familiar to Hippocrates, who described how “among the longheads, as soon as a baby is born its head is moulded by hand and later by the use of bandages and appliances until it becomes drawn out in a unique fashion” [Wells 1964: 163].

The significance of dental modification has been interpreted in a variety of ways, including rites of initiation, as having “magical” or religious connotations, and as status/kinship markers [Ivanovski 1901; Romero 1970; Khudaverdyan 1996, 2000, 2011*b*]. Much of the classificatory work was focused on the Americas, and involved largely descriptive accounts of archeological remains [Delfino 1948, Romero 1970]. Types were also created for description of the extreme variations in form and artistry.

The purpose of the present paper is to review surgical and ritual practices on living people in the Late Antiquity period on the Shirak Plateau (western Armenia). Morphological analysis of the material has revealed the heterogeneity in the population of the Shirak Plateau [Khudaverdyan 2000, 2009]. Intragroup analysis has revealed two groups within this population. The horizontal profile of the face in one of these groups (group II) is slightly attenuated. It should be noted that carriers of this anthropological type (group II) resemble representatives from Moldova (Nikolae-vka) and Turkmenistan (Meshreti-Takhta) [Khudaverdyan 2000]. The invasions of various tribes led gradually to the influx of outsiders among the native Armenians and to the dilution of their ranks on the plateau [Khudaverdyan 2000, 2009]. The Armenians lived at the crossroads of the ancient world, straddling the trade routes from China, Persia, India, and Arabia to and from Russia and Europe. Accordingly, Armenia has been an area of perpetual war and its history determined by international circumstances.

Although the majority of bioarcheological works carried out in Armenia over the past decade have focused on changes in community health over time [Khudaverdyan 2005, 2010*a,b*], osteometric study, especially craniology and odontology [Khudaverdyan 2009, 2011*a*], underscores the capacity of human skeletal remains to provide evidence for the reconstructing and tracking of many aspects of behavior and the effects of sociocultural change. More generally, artificial modification of skulls in Armenia in Late Antiquity may be related to emerging social complexity in a society and the need to differentiate among people, creating thus a body-marking niche study-area.

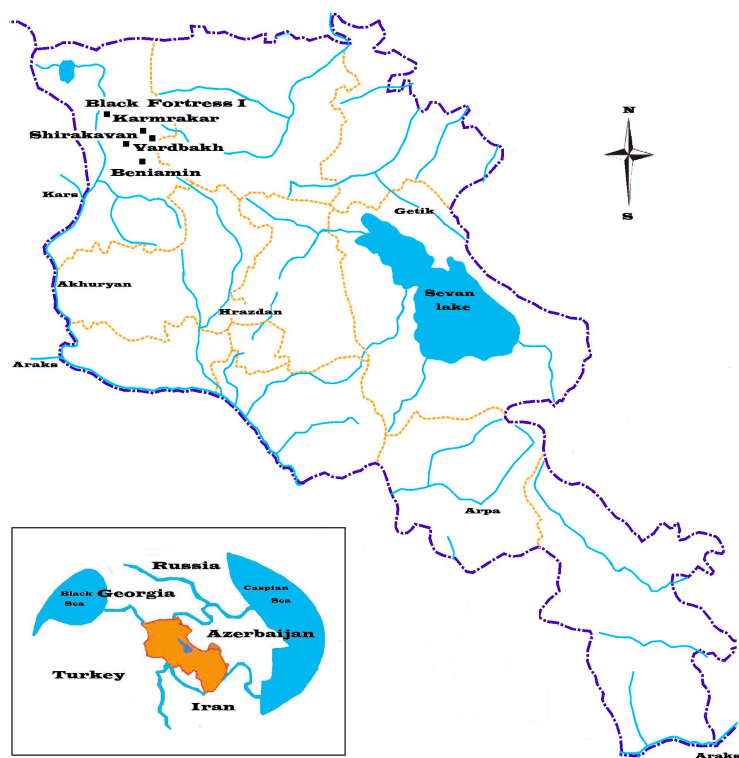

Fig. 1. Map of Armenia showing location of sites mentioned in the text

Materials and methods

The human remains analyzed for this paper were excavated by a Gyumri team under the direction of Stepan Ter-Markaryan (Vardbakh and the Black Fortress I), Felix Ter-Martirosov, Hamazasp Khachatryan, Larissa Eganyan (Beniamin, Shirakavan) and Haik Hakobyan (Karmrakar) at sites located on the Shirak Plateau (Fig. 1).

The *Beniamin* sample (Tabs. 1-2) was the largest in terms of number of burials. Altogether, about 217 individual interments were found. This sample contained at least 139 individuals (based on the number of skulls found). Of these, 50 were subadults and 89 were adults. Female individuals

predominated (68.2% of the 91 individuals sexed): 54.95% were adolescents and young adults (12-40 yrs.), and 13.2% were middle-aged and older adults. 31.9% of the sample were males: 16.5% were young adults and 15.4% were middle-aged and older adults) [Khudaverdyan 2000]. One adult individual was of undetermined sex (very fragmented skull, absent pelvic bones). The anthropological material uncovered during this period (1989–1997) was collected with the assistance of the author; these excavations are still ongoing.

A total of 14 skeletons was found during excavations in the *Vardbakh* cemetery (Tabs. 1-2). Most of these bones were in a good state of preservation and suitable

Table 1. Number of individuals from Beniamin, Vardbakh and Black Fortress I

Age classes	<i>Beniamin</i>			<i>Vardbakh</i>			<i>Black Fortress I</i>		
	♂	♀	?	♂	♀	?	♂	♀	?
Child I	-	-	43	-	-	2	-	-	2
Child II	-	-	4	-	-		-	-	2
Adolescent	-	3	-	-	-		-	-	1
Young adult	15	47	1	3	6	-	6	9	-
Middle adult	8	9	-	1	2	-	3	4	-
Old adult	6	3	-	-	-	-	1	-	-

♂ – male, ♀ – female, ? – indeterminate

Table 2. Age distribution of individuals from Beniamin, Vardbakh and Black Fortress I

Age	Child I		Child II		Adolescence		Young adult				Middle adult		Old adult
	0-2	2-7	7-9	9-12	12-15	15-20	20-25	25-30	30-35	35-40	40-45	45-50	>60
<i>Beniamin</i>													
<i>N</i>	32	11	4	0	3	0	8	6	20	29	12	5	5
<i>Vardbakh</i>													
<i>N</i>	2	0	0	0	0	0	3	3	0	3	3	1	0
<i>Black Fortress I</i>													
<i>N</i>	2	1	1	1	1	0	4	2	1	8	12	5	5

for determination of sex and age. The sex distribution was predominantly female (66.7% of the 12 individuals sexed). This was observed in all of the age categories: 50% were young adults (20-40 yrs.), 16.7% were middle-aged. 33.4% were males (25% being young adults and 8.4% being middle-aged or older adults).

The *Black Fortress* site (Tabs. 1-2) is remarkable due to the presence of two archaeological time periods of ancient Armenian history (Late Bronze Age and Ancient period: 1st c. BC – 3rd c. AD). The Black Fortress I site is a standard cemetery and has been excavated since 1993; this is still on-going [Ter-Markaryan 1991, Ter-Markaryan & Avagyan

2000, Avagyan 2003]. All of the burials appear to have been typical Late Antiquity period Armenian interments, oriented in an east-west direction. Of these, 5 were subadults and 23 were adults. The distribution of sex is predominantly female (56.6% of the 23 individuals sexed), 39.2% being young adults (20-40 yrs.) and 17.4% middle adults. 43.5% were males (26.1% were young adults and 17.4% middle and older adults).

Karmrakar. Many sites are found here within a large cemetery embracing two archaeological time periods (Late Bronze Age and Ancient period: 1st c. BC – 3rd c. AD). One individual was found here in 1992 [Khudaverdyan 2005]. The sample from

Shirakavan contains at least 13 individuals. No age or sex data of the skulls have been published (Anne Palikyan, pers. commun.).

Age-at-death and sex were assessed through the use of multiple indicators. Morphological features of the pelvis and cranium were used for the determination of sex [Phenice 1969, Buikstra & Ubelaker 1994]. A combination of pubic symphysis [Gilbert & McKern 1973, Meindl *et al.* 1985, Katz & Suchey 1986], auricular surface changes [Lovejoy *et al.* 1985], degree of epiphyseal union [Buikstra & Ubelaker 1994], and cranial suture closure [Meindl *et al.* 1985] were used for adult age estimation. For subadults, dental development and eruption, long bone length, and the appearance of ossification centres and epiphyseal fusion were used [Moorrees *et al.* 1963*a,b*; Ubelaker 1989; Buikstra & Ubelaker 1994].

Results

Trepanations

This section focuses on the possible the ancient trepanation of skulls at Black Fortress I and Shirakavan. Trepanned males may show evidence of cranial injuries which supports warfare theories (Fig. 2: Black Fortress I, burial 5, male, 31-36 yrs.). The oval aperture appearing on the left parietal bone (Fig. 2A), with marked elliptical defects on edges of the injury probably indicates that the person received a sharp blow from a weapon) [Khudaverdyan 2011*b*]. Since the aperture were on the left side of the skull it is suggested that a right-handed opponent standing opposite the victim caused the skull injury. The wound was quite large and oval and showed signs of healing.

Trepanation, achieved using a drilling technique, created the hole seen on the left lambdoid suture (Fig. 2B). From the ectocra-

nial aspect, the hole seemed to have resulted from two separate drilling attempts. The internal walls of the hole are laterally inclined. The endocranial image (Fig. 2C) provides information corroborating the theory that some degree of healing took place (shown by the arrow). It remains unclear how long the individual survived after the operation but it is certain that the individual was alive during the surgery. The mark of healing is almost too faint to examine macroscopically, and the survival period may be considered to have been relatively short. Trepanation was used probably to alleviate the cranial swelling resulting from war injury.

There are several examples of skulls that have both evidence of disease and trepanation. These diseases include, but are not limited to, scurvy, mastoiditis, ear infection, meningiomas, brain tumors, hydrocephaly, headaches, and seizures. The endocranial image shows the grooves and holes along with arachnoid granulations (Fig. 2D). Clear evidence of sclerosis inside the punctured hole is observed. Tumors and other cranial lesions leave small indentations in the interior of the skull. Gliomas, nonmalignant tumors, might have been the cause of trepanation in the male. Gliomas are slow-growing and would have caused increasing intracranial pressure. On the skull a number of indicators of physiological stress were found, including linear enamel hypoplasias and cold stress, indicating the impact of some stressor.

An ancient skull from Shirakavan also showed evidence of trepanation (Fig. 3). The individual was a juvenile (8-9 yrs. old). Trepanation, achieved using a drilling technique, created a hole which was noted on the right parietal bone of the funnel-shaped type (diameter = 8 mm). Since there was no evident biological reason to trepan this individual, and given the fact that this indi-

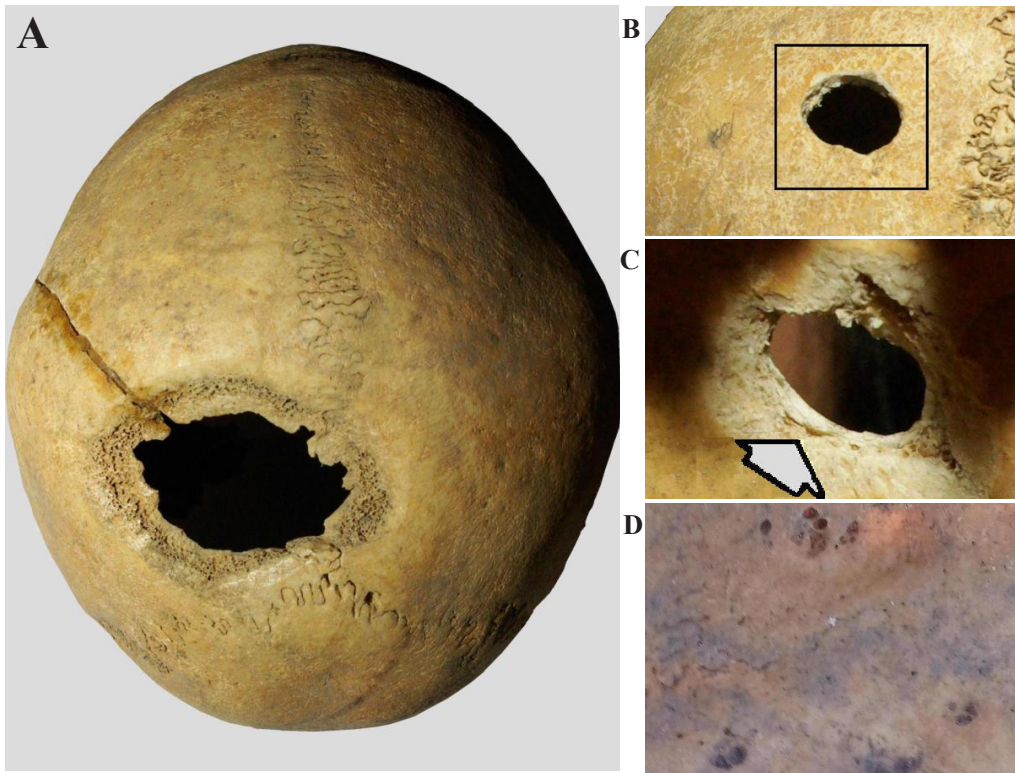


Fig. 2. Skull from Black Fortress I (burial 5): A - an oval wound; B - ectocranial view of trepanation; C - endocranial view of trepanation; D - signs of disease (photo A. Khudaverdyan)

vidual was quite young, it was possibly part of a ritual or religious ceremony. Perhaps the child died not from the trepanation process, but from complications of the surgery.



Fig. 3. Trepanation from Shirakavan (burial 11) (photo A. Khudaverdyan)

Artificial modification of skulls

In ancient Armenia, many cultural practices were aimed specifically at artificial modification of bones [Khudaverdyan 1996, 1997, 2000, 2011*b*]. The examined cranial series from the Beniamin site is particularly interesting as a case study for the interpretation of ancient Armenian body modification. Accurate traces of deliberate deformation of the head are noted in 4 adults and 26 children (see Figs. 4-5). The crania show varying degrees of modification. From the Beniamin burial ground, two types of deformation are observed: circular high (high ring) and low. The means and methods used for the skull deformations

were diverse. Bandages kerchiefs, wooden, bone and stone linings, etc. were used. On some of the deformed children's skulls (burial 18: 0,5-1,3 yrs.) traces of bandages are clearly apparent.

High ring deformation is found in the woman from burial 142 (Fig. 4). Similar deformations were observed in 10 children's skulls. In another case (low deformation; Fig. 5), pressure was apparently applied continuously to the top of the head, resulting in reduced cranial height and an increase in cranial breadth, which suggests the use of a very different appliance. Deliberate low deformations were noted in two male (burials 11 and 176) and a female skull (burial 75). Similar deformations are observed on 16 children's skulls. There may have been differences between the male and female head modifications, but the small sample size prevents any firm conclusions.

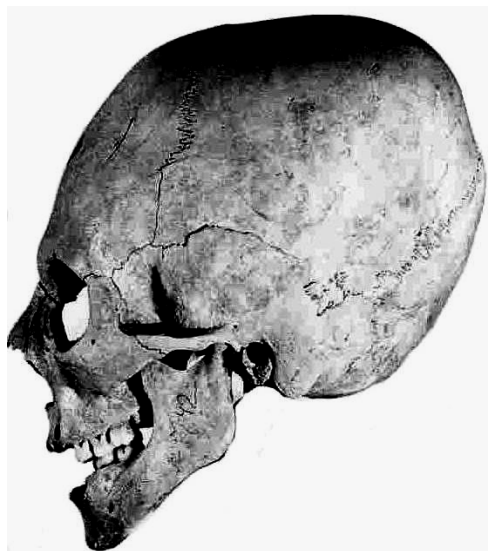


Fig. 4. Artificial deformation of a skull from Beniamin (burial 142, ♀ 20-30 yrs.) [Khuda-verdyan 2011b]

The third deformation type known from Armenia is the parietal type. This type was observed only on children's skulls (burials 6 and 16). On these skulls the early obliteration sagittal suture was observed so unintentional deformation cannot be excluded in this case.

Ring deformation was also revealed at the Karmrakar burial ground. Unfortunately, there is currently only one cranium available from the site. Traces of hard objects placed on both sides of the frontal bone close to the coronal suture are clearly discernible. One can also observe a flat area, 3.5 cm wide, on the superior temporal lines (Fig. 6). It is possible that the removal of all deforming influences was made before the termination of bone growth. The degree of deformity is directly dependent on age of the individual.

Accurate traces of deliberate deformation of a head were noted in two adults

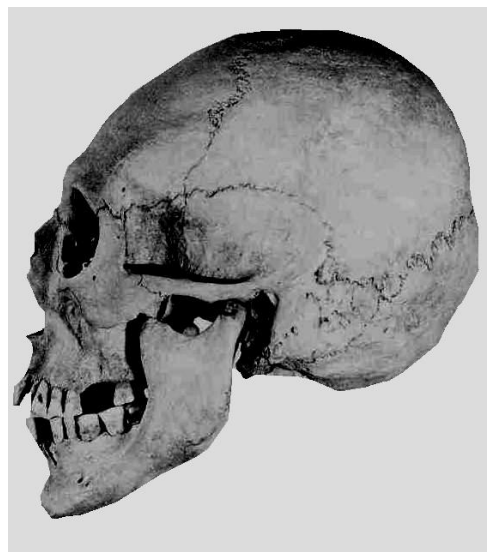

Fig. 5. Artificial deformation of a skull from Beniamin (burial 176, ♂ 30-40 yrs.) [Khuda-verdyan 2011b]

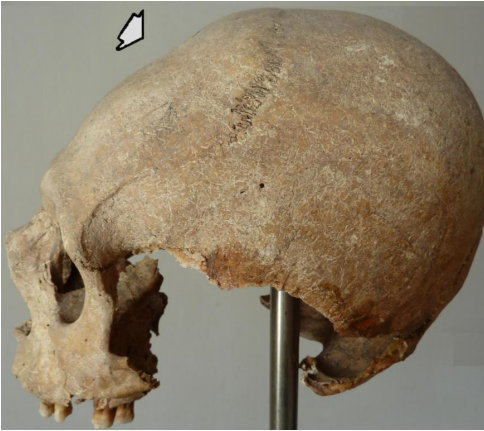

Fig. 6. Artificial deformation of a skull from Karmrakar (burial 1, ♂ 30-40 yrs.) (photo A. Khudaverdyan)

from Vardbakh (see Figs. 7-8). The crania show varying degrees of modification. The skull from burial 9 (woman, 30-40 yrs.) had an erect form of the annular type of cranial deformation (Fig. 7). It had been encircled by a 2 cm-wide bandage, which had been tied around the forehead, the parietal bones, and the squama occipitalis. Due to the circular pressure, the head had grown “high” and had acquired an approximately cone-shaped form, with a shallow depression in the middle of the squama frontalis and a flattened squama occipitalis.

The cranium from Vardbakh burial 3 (woman, 20-30 yrs.; Fig. 8A) exhibited the unambiguous markings of artificial and

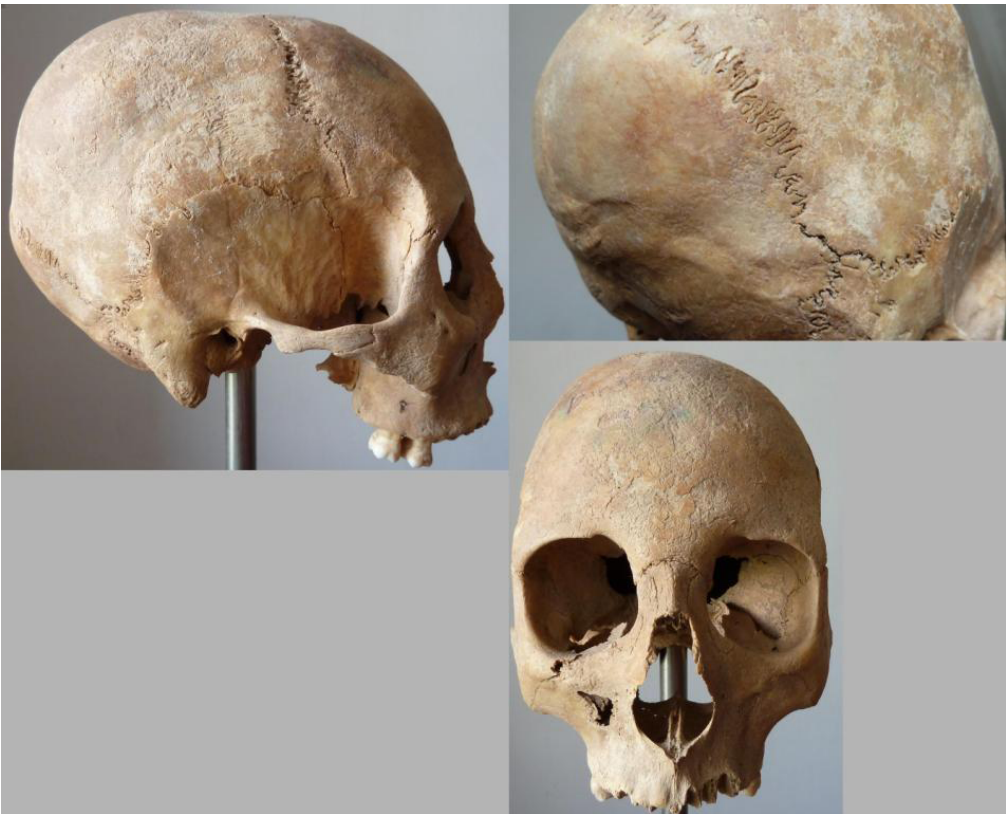

Fig. 7. Artificial deformation of a skull from Vardbakh (burial 9, ♀ 30-40 yrs.) (photo A. Khudaverdyan)

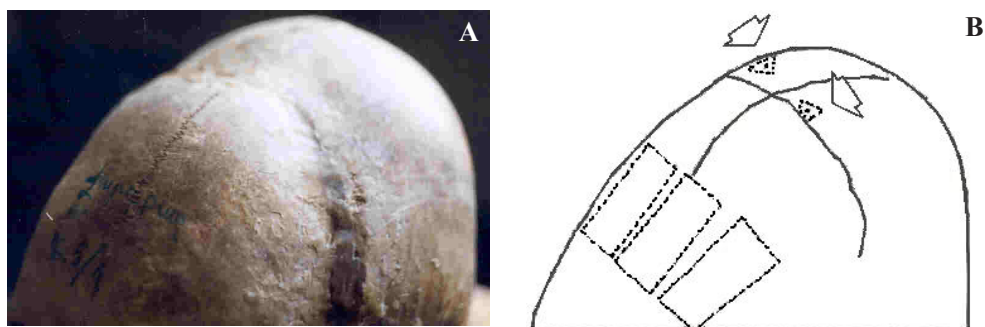


Fig. 8. Artificial deformation of a skull from Vardbakh (burial 3, ♀ 20-30 yrs.): A - photo, and B - drawing [Khudaverdyan 2010b]

intentional deformation, particularly in regard to a post-bregmatic saddle-shaped depression, demarcated by a low bulge of the frontal bone. At the intersection of the sagittal and the coronal sutures, a rare anatomical variation showing two depressions (0.5-0.7 mm) (shown by arrows; Fig. 8B) was observed. Coupled with a pronounced flattening and slant of the occipital bone, this peculiarity is suggestive of a head-shaping device attached with ligatures to the cranium during childhood. This device (and/or bandage) had caused shortening of

the cranium which had enlarged its height, resulting in the oblique form of the so-called annular type. The particular objective evidence of this is the symmetric arrangement of dot sites – on the skull rather than the sagittal and coronal sutures. As the pressure on the head was sufficiently long enough, it can be assumed that these objects were a form of headdress (Fig. 9) – an ornament or cult object, perhaps signifying high social status. Thus, artificial deformation of the skull had been used to denote defined status by its carrier.

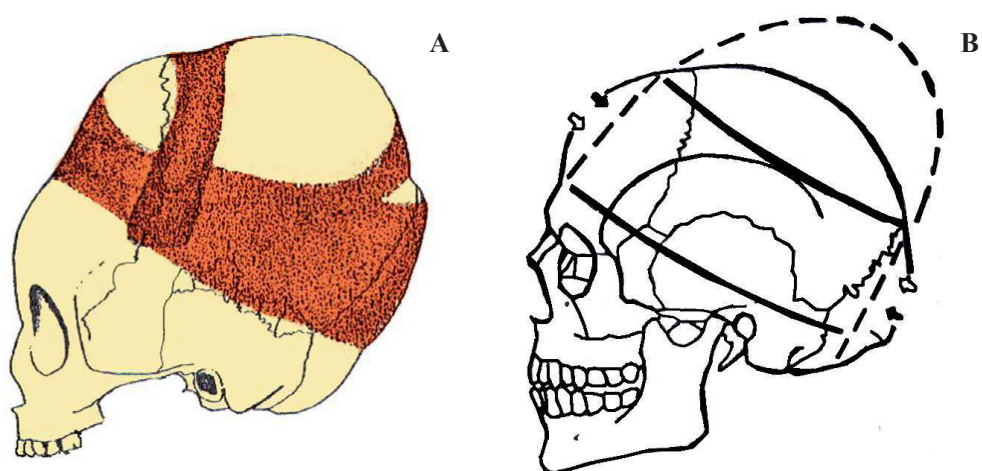


Fig. 9. Artificial skull deformation: A - showing a possible applications of bandages (modified after Winkler & Jungwirth [1978]); B - pointing to a possible location of a headdress [Khudaverdyan 2010b]




Fig. 10. Sculptures from: A - the village of Shakhat, B - the village of Shakhat, C - the city of Tejshebaini [Arakelyan 1976: tables III, IV, VII]

According to anthropologist Anne Palikyan (pers. commun.), skulls from Shirakavan also contain traces of deformations. The researcher did not elaborate further on the type or extent of the modifications. No photographs or drawings of these Shirakavan crania have been published. At present, the Shirakavan material does not contradict the evidence from other Shirak Plateau sites. Material from other areas of Armenia (burial grounds – Garni, Kar-chakhpiyr /1st c. BC – 3rd c. AD/) has not revealed evidence of artificial deformation or trepanation.

In Armenia, sculptural monuments in the form of stone idols are exhibited as male or female heads (Fig. 10) [Arakelyan 1976]. Although the study of sculptures is beyond the scope of this paper, they, however, and their stylized features, merit some attention. Thus, one headdress has a conical form (Fig. 10A), another – the trapezoid form, in the form of the cut off cone with slightly slanting or vertical lines on it (Fig. 10B), the third – the form of a column, tetrahedral or round section and coming to the end as a human head (Fig. 10C). As we see, both traditions, purposely deforming a head, and creating corresponding anthropomorphous sculptures,

are constantly conjoined, as though supplementing each other.

Artificial modification of teeth

Artificial body modification in Armenia was not limited to cranial deformation. A further ritual was practiced in antiquity on bone material in Armenia. This was the habit of filing and evulsing of teeth. I have defined a few distinctive types of artificial deformation of teeth in the ancient population from Beniamin. In the skeleton from burial 218, atrophy of three forward incisors in the top jaw, probably being a teeth-tearing ceremony (some researchers – see Ivanovski [1901], link this phenomenon with the “primitive” customs of chopping off of fingers and cutting off of ears, etc.) which took place here; in three subjects (burial 18, burial 58, burial 185) a forward tooth was filed down.

Burial 185 (female, 30-35 yrs; see Fig. 11) was unusual (on her knees) [Eganyan 2010]. Dental filing was observed on the maxillary central incisors. This procedure was performed with the help of a file or by means of friction on a tooth by a stone from gneiss or sandstone. The root canals of the deformed teeth had been opened

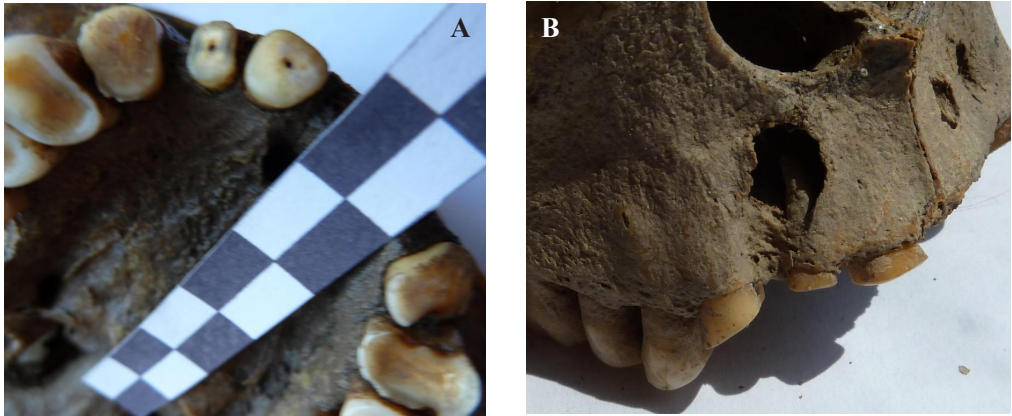


Fig. 11. Artificial modification of teeth (burial 185 from Beniamin): A - cut showing pulp canal space and dentine; B - infection and alveolar abscesses (photo A. Khudaverdyan)

(Fig. 11A), leading to infection and alveolar abscesses (Fig. 11B). Under the physiological or even pathological process of replacing worn dentin secondary dentin was activated and, consequently, root canals could be opened with any degree of wear subsequently, without extraneous intervention. The described procedures could be made only by the people with special training. It can be assumed that these persons combined the duties of an attendant of a cult and a doctor.

In one individual from the Black Fortress I (♀ 35-40 yrs.), the upper canine on the left side was intentionally broken off at the root, in addition to removal of the upper right first incisor. The incisor appears to have been ablated at around the beginning of adolescence.

The influence of human behavior on skeletal and dental tissues is certainly not limited to the results of intentional modification. Occupation-related activities may also lead to unusual modes of dental wear. Unintentional or accidental changes are seen as those caused by differential food preparation and consumption, by the use of teeth as tools and by inadvert-

ent changes caused by habitual activities. Mechanisms of wear include abrasion, attrition and erosion. The processes involved have been discussed as commencing with the loss of surface enamel, followed by a build up of secondary dentine to protect the pulp chamber. A peculiar form of dental wear found consistently in Late Antiquity cranial series from Vardbakh: Recognized effects include proportionately severe wear of the lower anterior teeth with labial rounding [Khudaverdyan 2010b]. Such a pattern of wear is usually attributed to use of the anterior teeth in processing animal or plant material and differs markedly from the deformation found in Beniamin (burial 185). This feature of the teeth may be associated either with malocclusion, or with the use of teeth for a non-masticatory activity [Merbs 1983, Erdal 2008].

Careful study of the odontologic materials from Shirak Plateau (Beniamin, Vardbakh) has revealed a correlation between the presence of bone thickenings (torus) and deformation of teeth. It can thus be assumed that the examined teeth had been exposed to additional loading.

Discussion

The practice of the abovementioned surgeries became fairly widespread, including in the Middle East, Armenia [Ghannan 1963; Kurth & Rohrer-Ertl 1981; Hershkovitz 1987; Özbek 1991, 1998; Açıkkol *et al.* 2009]. When our findings were compared with those from Achemhöyük, located in Anatolia, a site dating back to the Middle Bronze Age, the techniques of cranial trepanation from Black Fortress I (burial 5) did not differ from the Achemhöyük trepanation sample (Figs. 1-5: Açıkkol *et al.* 2009). Use of this technique was seen on a sample from Burzahom (India) (Figs. 1-2: Gandhi 2011). A single skull from Burzahom shows unambiguous evidence of multiple trepanation. In all, 11 attempts at trepanation are evident on the cranium.

When compared with samples from the Near East, the Black Fortress I trepanation seems similar to the sample from Jericho, Israel, where a Middle Bronze Age technique was used. There have been various suggestions as to why surgical intervention may have been performed in prehistoric society: in cases of trauma from battle or accident, cranial infections, headaches, convulsions, mental disease, and religious rituals, brain tumours, hydrocephaly, etc. [Ackerknecht 1947, Lisowsky 1967, Ortner & Putschar 1985, Roberts & Manchester 1995, Khudaverdyan 2011a]. Trepanation from Black Fortress I was used to alleviate the cranial swelling resulting from a war injury. The trepanning exhibited in the individual from Shirakavan, given that this individual was quite young, was possibly part of a ritual or religious ceremony. No signs of trauma or paleopathological lesions were found that could otherwise have affected the bone.

Although the idea of “creating man in the image and likeness of God” had world-

wide popularity, almost as widespread in traditional cultures was the attempt to “fix the work of the Creator”. And if some of these attempts have received a pragmatic interpretation, others still store secrets. In many cultures, and in various socio-cultural circumstances, we find proof of artificial shaping of the human skull. When our findings were compared with those from Caucasus, the techniques of cranial deformations from Armenia did not differ from those observed in the Caucasian samples. In Dagestan (Ginchi), at a site dating to the 4th millennium BC, the skull of a man with traces of artificial deformation was found [Gadzhiev 1975]. Firshtein [1974] and Batiieva [2008] found artificial deformation of skulls on the Lower Don during the Bronze Age. In tribes of the Catacomb cultures, Shevchenko [1986] discovered the presence of deformation. This custom, according to the researcher, was brought from the Near East through the Caucasus to the steppes of the Eastern Europe. In Transcaucasia (Beniamin, Shirakavan, Karmrakar, Vardbakh, Samtavro and Mingechayr) ring deformation had wide circulation in the Antiquity period (1st c. BC – 3rd c. AD) [Khudaverdyan 1997, 2000]. The skeletal material suggests that the practice seen in the Caucasus could in fact be part of a longer tradition, dating back to occurrences in the Near East. The ancient Hittites in the Middle East are known to have practiced head deformation [Dingwall 1931, Ferembach 1985]. According to Dingwall [1931], head deformation is still linked to high social status in Asia Minor, Kurdistan and India.

Tooth modification was extremely rare in ancient Armenia. To date, no other unambiguous examples of filing or artificial modification have been recorded. Relatively low frequencies of evidence for inten-

tional tooth modification in Armenia perhaps reflect the imitation of foreign practices rather than well-established traditions of a community on the fringes of Shirak Plateau. In this regard, the Benjamin and Black Fortress I series are unique. Moreover, the modified teeth were found in close association with modified cranial remains. There is support for the general idea that dental and cranial modifications are a means of identification, perhaps for the region or a lineage or of a political leader [Patterson 1987, Gertzen 1993, Blom *et al.* 1998, Khudaverdyan 2000, Lichtenfeld 2001, Torres-Rouff 2002]. The state had required newly arrived groups to adopt practices that would distinguish them from neighboring groups. It should be noted that some individuals from the Benjamin necropolis with artificial deformation of the head and teeth differ considerably morphologically from the others. The horizontal profile of their faces is a little less prominent [Khudaverdyan 2000]. A further analysis of the corresponding funerary contexts would help determine whether body modifications depicted either immigrants and/or a particular occupational or social group. Hopefully, new samples currently being excavated at Shirak Plateau will shed more light on these issues.

Conclusions

Artificial modification the human skull has been part of human culture from antiquity, and it was practiced on every continent. The two essential forms of this practice include trepanation – the deliberate, creation of a hole in the cranial vault – and the application of pressure on the head of infants or toddlers to alter the natural shape of the cranial vault. In the trepanation examples from the Shirak Plateau only the drilling

technique seems to have been employed. The trepanned male from Black Fortress I may show evidence of cranial injuries thus supporting the warfare hypothesis. The individual from Shirakavan was quite young, so the trepanning here was possibly part of a ritual or religious ceremony. However, the individuals from the Shirak Plateau show signs of healing indicating that they had survived the surgery and perhaps also whatever occasioned the need for trepanation.

In this paper, I have presented evidence that head deformation in ancient Armenia was practiced during relatively short time intervals and limited to a few sites. Different techniques can produce skull deformations, resulting in different morphological outcomes. Skull deformation by means of a circular bandage around the head was also found at these sites during this period. Accurate traces of point deformation of the head are noted in the individual from the ancient Vardbakh burial ground.

Evidence for dental changes in the archaeological record can be a valuable resource for information on cultural processes and social differentiation within cultures. It is suggested that modified teeth could have indicated social relationships, religious affiliations and even fashion. Possibly this ritual component of a given ceremony represented the transition from one social category to another. The phenomenon of artificial skull and teeth modification identified at ancient burials sites in Armenia certainly points to an emerging social complexity and class differentiation, and hence the need for social distinction, which in this case was accomplished through the use of body markings [Khudaverdyan 2000; Lorentz 2010]. Hopefully, new samples currently being excavated at the Shirak Plateau will advance the understanding around these issues.

Notes

Acknowledgements Many people contributed to this paper. I would like to express my deepest gratitude to my family – my mother Haykui, my brothers Hayk, Ryben and Syren for all they have done for me. Special thanks are also due to my wonderful teacher, Professor Vasilii E. Deriabin (Moscow) for all his help, encouragement, and confidence shown in me. I would like to thank Larissa Eganyan, Stepan Ter-Markaryan, Hamazasp Khachatryan, Haik Hakobyan and members of the archeological expeditions for the opportunity to study the human remains from their collections. I also wish to thank the two anonymous reviewers who provided constructive comments on the earlier versions of this paper, as well as the Editors of *Anthropological Review* – Professors Katarzyna A. Kaszycka and Jan Strzałko for their assistance.

References

- ARAKELYAN B.N., 1976, *Očerki po istorii iskyssstva drevnej Armenii (VI v. do n.e. – III v. n.e.) [Outlines of the history of ancient Armenian art (VI c. BC - III c. AD)]*, National Academy of Science of Armenia, Yerevan
- ACKERKNECHT E.H., 1947, *Primitive Surgery*, *Am. Anthropol.*, **49**, 25–45
- AÇIKKOL A., I. GÜNAY, E. AKPOLAT, E. GÜLEÇ, 2009, *A Middle Bronze Age case of trephination from central Anatolia, Turkey*, *Bull. Int. Assoc. Paleodont.*, **3**, 28–39
- AUFDERHEIDE A.C., C. RODRIGUEZ-MARTIN, 1998, *The Cambridge Encyclopedia of Human Paleopathology*, Cambridge University Press
- AVAGYAN I., 2003, *Sev Amroci” hushardcani dambaranasht [Black Fortress site and cemetery]*, [in:] *Hayastani hnaguin mshakytit [The ancient culture of Armenia]*, A. Qalantaryan, R. Badalyan (eds.), Mukhni, Yerevan, pp. 128–34
- BATIEVA E.F., 2008, *K voprosu ob iskyssstvennoi deformacii čerepa na Nižnem Donu v epohu srednej bronzy [To a question on artificial deformation of skull on the Lower Don during the average Bronze Age]*, [in:] *Aktualnye napravlenija antropologii [Current directions in anthropology]*, Institute of Archeology of the Russian Academy of Sciences, Moscow, pp. 26–33
- BROCA P., 1876, *Sur l'âge des sujets à la trépanation chirurgicale néolithique*, *Bull. Soc. d'Anthrop. Paris*, **11**, 572–76
- BROTHWELL D.R., 1994, *Ancient trephining: Multi-focal evolution or trans-world diffusion*, *J. Paleopathol.*, **6**, 129–38
- BLOM D.E., B. HALLGIMSSON, L. KENG, M.C. LOZADA, J.E. BUIKSTRA, 1998, *Tiwanaku “Colonization”: Bioarchaeological Implications for Migration in the Moquegua Valley, Peru*, *World Archaeology*, **30**, 238–61
- BUIKSTRA J.E., D.H. UBERLAKER, 1994, *Standards for the recording of human skeletal remains*, Seminar at the Field Museum of Natural History 44, Arkansas Archaeological Survey Research Series
- DELFINO A., 1948, *Alteraciones dento-maxilares intencionales de carater etnico-nuevo clasificacion*, *Revista del Museo de La Plata, Buenos Aires*
- DINGWALL E.I., 1931, *Artificial cranial deformation: A contribution to the study of the ethnic mutilations*, John Bale, Sons & Danielsson, London
- EGANYAN L.G., 2010, *Shiraki hnagitakan ev patma-azgagrakan hetazotytyunner [Archaeological and historical-ethnographic research at Shirak]*, vol. I, Gyumri, Yerevan
- ERDAL Y.S., 2005, *Ikiztepe Erken Tunç Çağı İnsanlarında Trepensasyon: Olası Nedenleri*, *Arkeometri Sonuçları Toplantısı*, **20**, 101–12
- ERDAL Y.S., 2008, *Occlusal grooves in anterior dentition among Kovuklukaya inhabitants (Sinop, Northern Anatolia, 10th century AD)*, *Int. J. Osteoarchaeol.*, **18**, 152–66
- FEREMBACH D., 1970, *Etude anthropologique des ossements humains néolithiques de Tell-Ramad, Syrie*, *L'Anthropologie*, **74**, 244–75
- FEREMBACH D., 1985, *Quelques coutumes et modes préhistoriques intéressant le crâne*, *Arqueologia (Porto)*, **12**, 47–56
- FIRSHTEIN B.B., 1974, *Materialy k antropologii naselenija epohi bronzy Nižnego Podon'ja [Anthropological materials from the Bronze Age Lower Don population]*, [in:] *Problemy antropologii i morfologii čeloveka [Problems of anthropology and human morphology]*, Science, Leningrad, pp. 98–123
- GADZHIEV A.G., 1975, *Drevnee naselenie Daghestana po dannym kraniologii [Craniological*

- data from the ancient Dagestan*], Moscow, Science
- GANDHI D., 2011, 'Brain surgery' during Harappan civilisation? The Hindu, <http://www.andaman.org/BOOK/reprints/sankhyan/burzahom.htm>
- GERTZEN P.C., 1993, *An Investigation into the Practice of Cranial Deformation among the Pre-Columbian Peoples of Northern Chile*, *Int. J. Osteoarchaeol.*, **3**, 87–98
- GHANNAN D., 1963, *Chronique archéologique*, *Revue biblique*, **70**, 421–23
- GILBERT B.M., T.W. MCKERN, 1973, *A method for aging the female os pubis*, *Am. J. Phys. Anthropol.*, **38**, 31–38
- HERSHKOVITZ I., 1987, *Trephination: The earliest case in the Middle East. Mitekufat Haeven*, *Journal Israel Prehistoric Soc.*, **20**, 128–35
- IVANOVSKI A.A., 1901, *Zuby u različnyh čelovečeskih ras [Teeth in various human races]*, *Russian Anthropological Journal* **3-4**, 203–13
- KATZ D., J.M. SUCHEY, 1986, *Age determination of the male os pubis*, *Am. J. Phys. Anthropol.*, **69**, 427–35
- KHUDAVERDYAN A.Yu., 1996, *Iskysstvenno deformirovannye zuby iz raskopok Beniaminskogo mogil'nika [Artificially deformed teeth from the Benjamin burial site]*, *Bulletin of the Yerevan University*, **2 (89)**, 215–17
- KHUDAVERDYAN A.Yu., 1997, *Iskysstvenno-deformirovannye čerepa i zuby iz pogrebenij antičnogo mogil'nika Beniamin [Artificially-deformed skulls and teeth from the ancient burial site at Benjamin]*, *Bulletin of Social Studies, Armenian Academy of Sciences*, **2 (595)**, 138–44
- KHUDAVERDYAN A.Yu., 2000, *Naselenie Armjanskogo nagor'ja v antičnuij epohu (po antropologičeskim dannym Beniaminskogo mogil'nika [Data on the population of the Armenian Highland from the Benjamin burial site]*, Big Tigran, Yerevan
- KHUDAVERDYAN A.Yu., 2005, *Atlas paleopatologičeskijh nahodok na territorii Armenii [Atlas of paleopathological findings in Armenia]*, Van Aryan, Yerevan
- KHUDAVERDYAN A. Yu., 2009, *Naselenie Armjanskogo nagor'ja v epohu bronzy. Etnogenez i etničeskaja istorija [The Bronze Age population of the Armenian Highland: Ethnogenesis and ethnic history]*, Van Aryan, Yerevan
- KHUDAVERDYAN A., 2010a, *Pattern of disease in three 1st century BC - 3rd century AD burials from Beniamin, Vardbakh and the Black Fortress I, Shiraksky Plateau (Armenia)*, *Journal of Paleopathology (Italy)*, **22**, 15–41
- KHUDAVERDYAN A., 2010b, *Palaeopathology of human remains from Vardbakh and the Black Fortress I, Armenia*, *Bioarchaeology of the Near East*, **4**, 1–23
- KHUDAVERDYAN A., 2011a, *Migrations in the Eurasian steppes in the light of paleoanthropological data*, *Mankind Quarterly*, **51 (4)**, 387–463
- KHUDAVERDYAN A., 2011b, *Artificial modification of skulls and teeth from ancient burials in Armenia*, *Anthropos*, **106 (2)**, 602–9
- KURTH G., O. ROHER-ERTL, 1981, *On the anthropology of the Mesolithic to Chalcolithic human remains from the Tell es-Sultan in Jericho, Jordan*, [in:] *Excavations at Jericho*, K.M. Kenyon (ed.), British School of Archaeology, Jerusalem, pp. 407–99
- LICHTENFELD M., 2001, *Artificial Cranial Modification in the Jequetepeque Valley, Peru*, Master's thesis, University of Western Ontario, London, Ontario
- LISOWSKY F.P., 1967, *Prehistoric and Early Historic Trepanation*, [in:] *Diseases in Antiquity*, D. Brothwell, A. Sandison (eds.), C.C. Thomas, Springfield, pp. 651–72
- LORENTZ K.O., 2010, *Ubaid neadshaping: Negotiations of identity through physical appearance?*, [in:] *The Ubaid expansion? Cultural meaning, identity and lead-up to urbanism*, *International Workshop held at Grey College, University of Durham*, 20-22 April 2006, R.A. Carter, P. Graham (eds.), University of Chicago, Chicago, pp. 125–48
- LOVEJOY C.O., R.S. MEINDL, T.R. PRYZBECK, R.P. MENSFORTH, 1985, *Chronological metamorphosis of the auricular surface of the ilium: A new method for the determination of adult skeletal age at death*, *Am. J. Phys. Anthropol.*, **68**, 15–28
- MARGETTS L., 1967, *Trepanation of the skull by the medicine-men of primitive cultures, with particular reference to present-day native East African practice*, [in:] *Diseases in Antiquity*, D. Brothwell, A.T. Sandison (eds.), t. 11, Charles C. Thomas, Springfield, Il., pp. 673–701

- MERBS C.F., 1983, *Patterns of activity-included pathology in a Canadian Inuit population*, Archaeological Survey of Canada, Mercury Series 119, National Museum of Man, Ottawa
- MEIKLEJOHN C., A. AGELARAKIS, P.A. AKKERMANS, P.E.L. SMITH, R. SOLECKI, 1992, *Artificial cranial deformation in the proto-neolithic and neolithic Near East and its possible origin: Evidence from four sites*, *Paléorient*, **18/2**, 83–97
- MEINDL R.S., C.O. LOVEJOY, R.P. MENSFORTH, L.D. CARLOS, 1985, *Accuracy and direction of error in the sexing of the skeleton: Implications for paleodemography*, *Am. J. Phys. Anthropol.*, **68**, 79–85
- MOORREES C.F., E.A. FANNING, E.E. HUNT, 1963a, *Formation and resorption of three deciduous teeth in children*, *Am. J. Phys. Anthropol.*, **21**, 205–13
- MOORREES C.F., E.A. FANNING, E.E. HUNT, 1963b, *Age variation of formation stages for ten permanent teeth*, *J. Dental Research*, **42**, 1490–502
- ORTNER D.J., W.G.J. PUTSCHAR, 1985, *Identification of Pathological Conditions in Human Skeletal Remains*, Smithsonian Contributions to Anthropology No. 28, Washington
- ÖZBEK M., 1974, *A propos des déformations craniennes artificielles observées au Proche Orient*, *Paleorient*, **2**, 469–76
- ÖZBEK M., 1991, *Aşıklı Höyük Neolitik İnsanları*, *Arkeometri Sonuçları Toplantısı*, **7**, 145–60
- ÖZBEK M., 1998, *Çayönü'nde Kafatası Delgi Operasyonu*, *Hacettepe Üniversitesi Edebiyat Fakültesi Dergisi, Cumhuriyetimizin 75. Yılı Özel Sayısı*, 109–26
- PATTERSON T.C., 1987, *Tribes, Chiefdoms, and Kingdoms in the Inca Empire*, [in:] *Power Relations and State Formation*, T.C. Patterson, C.W. Gailey (eds.), American Anthropol. Assoc., Washington, pp. 121–31
- PHENICE T.W., 1969, *A newly developed visual method of sexing the os pubis*, *Am. J. Phys. Anthropol.*, **30**, 297–302
- ROBERTS C., K. MANCHESTER, 1995, *The Archaeology of Disease*, Cornell University Press, New York
- ROMERO J., 1970, *Dental Mutilation, Trephination and Cranial Deformation*, [in:] *The Handbook of Middle American Indians*, vol. 9, R. Wauchope (ed.), Univ. of Texas Press, Austin, pp. 50–67
- RUFFER M.A., 1918, *Studies in palaeopathology: Some recent researches on prehistoric trephinning*, *J. Path. Bad.*, **22**, 90–104
- SENYUREK M.S., S. TUNAKAN, 1951, *Seyh Hoyuk iskeletleri*, *Belleten*, **15**, 431–45
- SHEVCHENKO A.V., 1986, *Antropologia nasele-nija južno-russih stepej v epohu bronzy [Anthropology of the population of South Russian steppes during the Bronze Age]*, [in:] *Antropologia sovremennogo i drevnego naselenia Evropeiskoi časti SSSR [Anthropology of the modern and ancient populations of the European part of the USSR]*, Leningrad, Science, pp. 121–215
- TER-MARKARYAN S., 1991, *Kumairi tangarani Vardbakh dambaranashti peggumner [Excavation of employees of Gumry museum at the ancient Vardbakh cemetery]*, [in:] *Scientific session devoted to results of field archaeological researches in Republic of Armenia*, G. Tiratsyan (ed.), Institute of Archaeology and Ethnography, Yerevan, pp. 79–80
- TER-MARKARYAN S., I. AVAGYAN, 2000, *“Sev Berd” hushardcani bnakatex ev dambaranasht [Black Fortress site and cemetery]*, [in:] *Shiraki patmamshakytayin dzarangtyyn [Shirak's historical and cultural heritage]*, S. Hairapetya (ed.), Gyumri, Gitutyun, pp. 9–11
- TRINKAUS E., 1983, *The Shanidar Neandertals*, Academic Press, New York
- TORRES-ROUFF C., 2002, *Cranial Vault Modification and Ethnicity in Middle Horizon San Pedro de Atacama Chile*, *Curr. Anthropol.*, **43**, 163–72
- UBELAKER D., 1989, *Human skeletal remains. Excavation, analysis, interpretation*, Taraxacum, Washington
- WELLS C., 1964, *Bones, bodies and disease*, Thames and Hudson, London
- WINKLER E.-M., J. JUNGWIRTH, 1978, *Ein Kinderskelett mit deformiertem Schädel aus Schiltern in Niederösterreich. Zur Geschichte und Technik der künstlichen Schädeldeformierung in Österreich*, *Fundber. aus Österr.*, **17**, 197–209

Streszczenie

Chirurgia jest jedną z najstarszych dziedzin wiedzy medycznej. W praktyce antropologicznej do trepanacji zalicza się otwory wykonane w czaszce zarówno w celach rytualnych, jak i leczniczych. Takim leczniczym zabiegiem są trepanacje dla usunięcia odłamków kostnych powstałych po urazach kości czaszki, a także przy uporczywych bólach głowy, epilepsji i innych chorobach. Obserwacje morfologii czaszek stwarzają również możliwość zbadania dwóch rodzajów sztucznych deformacji głowy: puszki mózgowej i zębów. Celowe działanie na mózgowicę z zamiarem zmienienia kształtu głowy stwierdzano w wielu grupach etnicznych, różniących się geograficznie i chronologicznie. Motywy zamierzonej deformacji głowy mogą być bardzo różne: podkreślenie wyróżnionej pozycji społecznej i odróżnienie od obcoplemieńców, poprawienie „niewłaściwego” kształtu czaszki i uzyskanie „pięknych” proporcji głowy wymaganych lokalną normą estetyczną, itp. Motywem deformacji zębów także może być uleganie normie estetycznej lub wskazywanie statusu społecznego danego człowieka.

Podstawowym materiałem niniejszych badań były znaleziska kraniologiczne ekspedycji z terenu równiny Szirak w Armenii (ryc. 1). Analizowany materiał składa się z 5 serii: Benjamin, Wardbach, Szirakawan, Karmrakar i Czarna Twierdza I (patrz tab. 1-2). Wśród zbadanych materiałów znalazły się dwie czaszki z epoki późno antycznej ze śladami trepanacji (ryc. 2B, 2C i 3). Trepanacje wykonano metodą wiercenia. W obu przypadkach śródkościę było zasklepienie na całym brzegu otworu, co oznacza, że trepanowani żyli po operacji.

Na równinie Szirak odkryto nieznaną wcześniej czaszki z epoki antycznej ze sztucznymi deformacjami. Wykonywanie celowej pierścieniowej deformacji głowy stosowała ludność ze stanowisk Veniamin, Wardbach, Szirakawan i Karmrakar. Na cmentarzysku w Benjamin (u 4 dorosłych i 26 dzieci) występują deformacje pierścieniowe czołowo-potyliczne dwóch typów: o formie zbliżonej do stożka (ryc. 5) i formie wieżowej (ryc. 4). Pierścieniowa deformacja występuje także u osobnika z Karmrakar (ryc. 6). Wyraźne ślady celowej deformacji pierścieniowej (ryc. 7) i punktowej (ryc. 8) stwierdzono także u osobników z antycznego cmentarzyska Wardbach. Warto dodać, że na terenach Wyżyny Armeńskiej spotyka się znaleziska rzeźb – kamiennych idoli zwieńczonych kobiecą lub męską głową (ryc. 10). U jednych przybranie głowy ma formę stożkową, u innych – ściętego stożka. U przedstawicieli starożytnej ludności Armenii z cmentarzyska Benjamin stwierdzono ponadto sztuczne deformacje zębów – u trzech osobników (ryc. 11) przednie zęby były spiłowane.

Wydaje się, że zwyczaj sztucznego deformowania głowy i zębów wiązał się z rosnącą złożonością społeczeństwa i wynikającą stąd potrzebą znakowania różnic społecznych.